ArnotHealth
Graduate Medical Education

DIFFUSE MALIGNANT PERITONEAL MESOTHELIOMA - BIPHASIC TYPE

Wang K, MD, Mughal S, MD, Place L, DO, Asrar A, MD, Foster D, DO

Department of Family Medicine, Arnot Ogden Medical Center, Elmira, New York

LECOMT
LAKE ERIE CONSORTIUM FOR OSTEOPATHIC MEDICAL TRAINING

Abstract:

This report describes a rare case of diffuse malignant biphasic (mixed epithelioid and sarcomatous) mesothelioma arising in the peritoneum. A 50-year-old male with a history of asbestos exposure, complaining of abdominal pain, was found via computed tomography (CT) to have multiple omental nodules. The excised omental nodule was histologically and immunohistochemically consistent with a malignant mesothelioma with mixed epithelioid and sarcomatous type and no distant metastasis. The diagnosis of malignant biphasic mesothelioma arising in the peritoneum was appropriate because there was no evidence of any other primary tumor.

Introduction:

Malignant mesothelioma (MM) is the most common primary tumor of the serosal membrane of the pleura, peritoneum, and pericardium [1]. Histologic classification of MM includes epithelial, sarcomatous, and biphasic subtypes according to World Health Organization (WHO). Simple epithelioid MM is the most common histologic type of the disease. Sarcomatous and biphasic MM are relatively rare [2]. Pain is the most common symptom (recorded in 33% of patients), increased abdominal girth occurred in 31%, increased abdominal girth and pain 5% and a new onset hernia in 12%. In an additional 14% of patients, a variety of other clinical findings led to the diagnosis [3]. Malignant peritoneal mesothelioma is difficult to diagnose because clinical symptoms and findings are nonspecific. The median survival is approximately 8 months, mainly because of a lack of effective treatment [4].

Case Presentation:

50 years old male, with approximately 15-20 years history of asbestos exposure as metal press operator and a former tobacco smoker with past medical history of benign essential hypertension, hyperlipidemia, type 2 diabetes, asthma, constipation and morbid obesity (BMI 40) complained of intermittent epigastric pain and fullness for one and a half month. He was seen at Arnot Emergency Department in July 2021, where he was noted to have an umbilical hernia and several nodules which appeared to be peritoneal in origin. CT abdomen and pelvis at AOMC shows recurrent umbilical hernia containing mesenteric fat and omental soft tissue nodule. Multiple omental nodules attributed to metastatic seeding, the largest slightly to the left of mid-line measuring 3.7x3.5cm, increased in size from previous study (Figure 1). No small bowel obstruction nor ileus was noted.

Diagnostic laparoscopy with omental biopsy and primary hernia repair was performed at AOMC. Pathology from omental biopsy was originally reported as high-grade malignant neoplasm. An initial battery of immunizations is performed at an outside institution as shown in table 1. The morphologic features and immunohistochemical results support the diagnosis of malignant mesothelioma and the morphology is consistent with biphasic type (Figure 2).

Patient was also seen at Roswell Park Cancer Center and plan was discussed with the patient to do systemic chemotherapy with 4-6 cycles using Cisplatin Pemetrexed Q 3 weeks (with Vitamin B12 injections Q 9 weeks and folic acid 1 mg PO daily) then re-assess with CT abdomen and pelvis to evaluate the response. If disease remains stable, plan would be cytoreduction and HIPEC. Patient received 3 cycles of chemotherapy and unfortunately did not tolerate it well and ended up in ED with worsening abdominal pain, nausea and vomiting. CT findings show significant increase in abdominal mass, now measuring up to 10 cm with increase in surrounding nodularity with infiltrative changes in the adjacent fat and moderate free fluid. He also had another repeat CT abdomen pelvis with contrast which showed multiple collections of fluid within the mesenteric fat without any connections to the bowel. Patient was admitted to the hospital multiple times requiring palliative indwelling catheter for intra peritoneal fluid pockets and was prescribed short course of Levaquin prophylactically which was later switched to Augmentin. Fluid culture was done in every hospital admission but turned out sterile every time. Patient developed BAM (bile acid malabsorption) secondary to GI malignancy which consist of intractable nausea and bilious vomiting along with bilious diarrhea, for this reason Ursodeoxycholic acid has been prescribed.

He was getting morphine and fentanyl patch for pain, MiraLAX, Senna, Colace and Dulcolax for constipation and Zofran and Compazine for nausea initially which was switched to Haldol later during treatment because of intractable nausea and vomiting since the chemotherapy stopped. Patient went to Sloan Memorial Kettering in NYC for second opinion. He was told that there is no possible intervention at this time due to his generalized weakness and would be a poor surgical candidate for abdominal decompression surgery. He was also told that his prognosis is poor with limited life span and would require a miracle if he wants to get better. They recommended him to pursue either palliative or hospice care. Patient was receiving home hospice care since January 2022 and passed away on March 6, 2022, of cardiac arrest secondary to pleural effusion.

Table 1: Immunohistochemical findings of present case

Antibody	Reaction
AE1/AE3	+
Vimentin	+
Calretinin	+
Pankeratin	+
GATA3	+
WT-1	+
D2-40	+
CD45	-
CK5/6	-
CK20	-
CK7	-
p-40	-
p-63	-
BerEp4	-
Claudin-4	-

Table 1: Immunohitochemical findings of present case.

Figure 1: CT abdomen and pelvis (sagittal view) shows mass just left of the umbilicus and several peritoneal nodules just above the intestine.

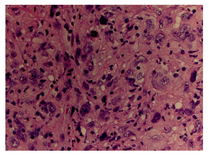

Figure 2 (a): H&E stain: mixed epithelial and sarcomatous cells

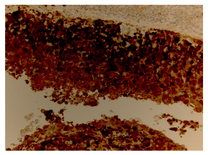

Figure 2 (b): tumor cells stained positively for calretinin

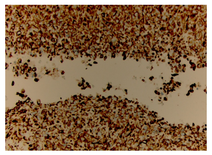

Figure 2 (c): tumor cells stained positively for Vimentin

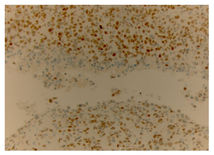

Figure 2 (d): tumor cells stained positive for GATA3

Discussion:

•The peritoneum is the second most common location for malignant mesotheliomas, about 10–25% of patients diagnosed with the disease, the remainder being primarily thoracic. Despite their increased rate of occurrence, they remain rare, at a rate of 2.2 per million per year in the USA. Despite a variable growth rate, these cancers often present with remarkably florid and rapid progression [4].

•They are predominantly found in middle-aged and elderly men, usually of low socioeconomic status. Since it's a rare tumor, no recognized staging system is available, nor are there uniformly accepted/established treatment protocols for these patients [4].

•Diagnosis can be very difficult preoperatively, as imaging, cytology and histological findings are usually not specific and overlap with other tumors. Immunohistochemistry is currently the best method of diagnosis. Calretinin, Vimentin, AE1/AE3 and GATA3 are the best positive markers for differentiating biphasic malignant mesothelioma from other sub-types.

•Asbestos exposure is the only known risk factor, related to the tumor in as many as 87% of cases in some series. Initial presenting symptoms include dull abdominal pain, distention or mass, ascites, weight loss, fever, bowel obstruction, thrombocytosis and fatigue. Two hypotheses exist as to how asbestos exposure leads to peritoneal cancer. The first is that the crystals are ingested and over time slowly migrate from the lumen of the GI tract to the peritoneum. The second hypothesis is that the crystals are carried to the peritoneum via the lymphatic system. Diffuse malignant peritoneal mesotheliomas present in most of the cases as multiple plaques or nodules over the peritoneum, sometimes associated with dense adhesions, shortening of the mesentery and almost always associated with ascites. The tumor can very rarely present as a solitary mass [4].

•Prognosis is poor and surgery is often not an option, as most malignant peritoneal mesotheliomas are in their advanced stages at the time of discovery. This condition has been traditionally regarded as a rapidly lethal disease, with a mean survival of 8 months following diagnosis. Yan et al published the data that shows surgical debulking and HIPEC can increase survival for up to 53 months. On multivariate analysis, the epithelial subtype, absence of lymph node metastasis, completeness of cytoreduction and HIPEC were identified as prognostic factors independently associated with improved survival [4].

References:

1. Kohno, M., Maruyama, R., Kitagawa, D., Sugimachi, K., Kinjo, M., & Higashi, H. (2014). Localized biphasic type malignant mesothelioma arising in the peritoneum: Report of a case. Thoracic Cancer, 5(1), 74-77.

2. Liu, Y., Wu, J., Zhao, Y., Zhang, P., Hua, Z., Dong, W., ... & Liu, A. (2020). Localized biphasic malignant mesothelioma presenting as a giant pelvic wall mass: a rare case report and literature review. BMC Medical Imaging, 20(1), 1-7

3. Miyata, T., Fujiwara, Y., Nishijima, K., Futagami, F., Nakamura, T., & Takamura, H. (2019). Localized multiple malignant epithelioid peritoneal mesotheliomas arising from the hepatoduodenal ligament and diaphragm: a case report. Journal of Medical Case Reports, 13(1), 1-6.

4. Mino, J. S., Monteiro, R., Pigalarga, R., Varghese, S., Guisto, L., & Rezac, C. (2014). Diffuse malignant epithelioid mesothelioma in a background of benign multicystic peritoneal mesothelioma: a case report and review of the literature. Case Reports, 2014, bcr2013200212.

For additional information please contact:
Kaiser Wang kaiser.wang@arnothealth.org
Sadaf Mughal sadaf.mughal@arnothealth.org
Lucas Place lucas.place@arnothealth.org
Aeman Asrar aeman.asrar@arnothealth.org