ArnotHealth
Graduate Medical Education

Rare Case of Right Sided Infective Endocarditis with Tricuspid Valve and RVOT Mural Vegetations:

John Yavorski DO, Laura Carlson DO and William DeLuccia MD
Department of Cardiology, Arnot Ogden Medical Center, Elmira NY

LECOMT
LAKE ERIE CONSORTIUM FOR OSTEOPATHIC MEDICAL TRAINING

Introduction

- Right sided endocarditis is much less common than left sided endocarditis, accounting for approximately 5-10% of cases. The most common predisposing factor is IV drug use; the most common organism is *Staphylococcus aureus*.
- Vegetations are located on the tricuspid valve in 90% of cases, with the pulmonic valve involved less frequently.[1] Vegetations in the right ventricular infundibulum or septum have not been reported as frequently.[2,3] Our case involves vegetations on the tricuspid valve and right infundibulum.

Case Presentation

- Patient is a 24-year-old female with a past medical history of IV drug use who presented to the emergency department complaining of low back pain that radiated down her left leg and left leg weakness. She admitted to a petechial rash of her lower extremitites as well as a fever for several nights. On presentation she was febrile at 104F with O2 sat of 88% on room air.
- Past medical history: IV drug use (heroin, methamphetamines), opioid dependance (remission), hepatitis C, tobacco use, migraines, anxiety
- Surgical history/family history/allergies: none
- Physical exam: petechial rash from the shins to knees bilaterally, no Osler nodes or Janeway lesions noted

Lab Values

- Blood cultures: 2/2 postive for *Staphylococcus aureus.*
- Urine drug screen positive for amphetamines and buprenorphine. Anaplasma, ehrichia, borrelia and babesia antibodies: negative. CRP 24 and ESR 106. D-dimer 2518. Iron 10, iron binding capacity 115, 8.7% iron saturation. CBC: WBC 10.4 (highest 11.7), hemoblogin 9.8 (lowest 6.7), hematocrit 29.2, platelets 608. CMP: Na 131, Cl 96, albumin 2.9, alkaline phosphatase 169.

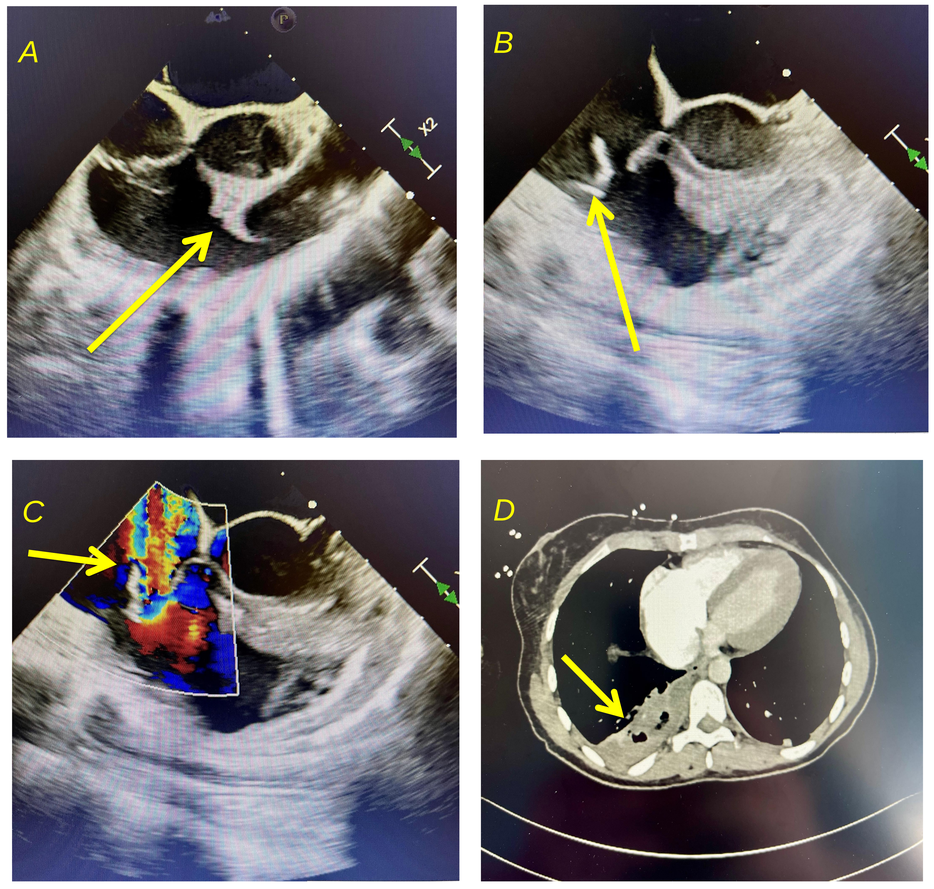

Image A: TEE showing vegetation on right ventricular infundibulum/ RVOT (arrow). Image B: TEE showing slender vegetation on anterior leaflet of tricuspid valve (arrow). Image C: Severe tricuspid regurgitation jet noted on TEE (arrow). Image D: CT chest angiogram showing dense consolidation in right lower lobe (arrow). There were also other areas in bilateral lungs showing solid and cystic appearing nodules consistent with septic emboli.

Imaging

- CT thoracic/lumber spine on day 1: multifocal pulmonary cavitation that may represent septic emboli.
- TTE on day 2: no vegetations on aortic, mitral or tricuspid valves. Tricuspid valve – mid systolic bowing without prolapse of the anterior leaflet. Pulmonary valve not visualized.
- TEE on day 4: large mobile vegetation (1.45 x 1.8 cm) in the right infundibulum, large slender mobile vegetation (1.2 x 0.2 cm) on the anterior leaflet of the tricuspid valve with moderate to severe TR.
- Limited TTE on day 9: 1.4 x 0.8 cm mobile mass on the right ventricular infundibulum/septum - size unchanged.

Hospital Course

- Patient received rocephin and vancomycin in the ER. This was changed to cefazolin after blood cultures resulted MSSA. Throughout her hospital stay, patient's chest pain, shortness of breath, back pain and leg pain improved. She was started on ferrous sulfate for iron deficiency anemia and did receive a unit of PRBC's for a hgb of 6.7 during her hospital stay. Case discussed with CT surgery with no surgical intervention required. It was determined that she should receive continued cefazolin at an inpatient swing bed; she was transferred.

Follow-Up

- It was recommended that patient have a TTE following discharge as well as TEE eventually. TTE 2.5 weeks post-discharge revealed a mobile vegetations on the RVOT/subvalvular apparatus and right ventricular infundibulum/septum. Patient has not showed for a follow-up visit with cardiology at this time.

References
1. Shmueli, H., Thomas, F., Flint, N., Setia, G., Janjic, A., & Siegel, R. J. (2020). Right-Sided Infective Endocarditis 2020: Challenges and Updates in Diagnosis and Treatment. In Journal of the American Heart Association (Vol. 9, Issue 15). Ovid Technologies (Wolters Kluwer Health).
2. Jeong, J. I., Shin, J. H., Kim, W., Cho, Y. K., Lee, H. M., Kim, H. S., Tahk, S. J., & Choi, B.-I. W. (1996). A Case of Right Ventricular Infundibular and Pulmonic Valve Infective Endocarditis. In Korean Circulation Journal (Vol. 26, Issue 1, p. 149). The Korean Society of Cardiology.
3. Jawad, M., & Cardozo, S. (2015). RVOT mural and mitral valve endocarditis: A case report. In Indian Heart Journal (Vol. 67, Issue 6, pp. 595–597). Elsevier BV.